



Retained air rifle pallet presenting as a breast lump eight years after injury

*Corresponding Author: **Saif Al-Sahee**

Email: saif.al-sahee@nhs.net

Abstract

Introduction: Foreign bodies within the breast are uncommon and may present diagnostic and management challenges, particularly when non-iatrogenic in origin. Retained airgun pellets are rarely reported and may mimic breast pathology years after the initial injury.

Case presentation: We report the case of a 25-year-old female who presented with a palpable breast lump eight years after sustaining an air rifle injury at the age of 17. Initial assessment at the time of injury included clinical examination and imaging, with no intervention performed. The patient subsequently developed a painless, firm mass in the left breast, prompting further evaluation several years later. Ultrasound imaging confirmed a retained foreign body, while blood lead level was within normal limits. The foreign body was successfully excised under local anaesthesia without complications. Histopathological analysis was not required, and the patient had an uneventful recovery.

Discussion: Retained foreign bodies in the breast can remain asymptomatic for prolonged periods and may present as palpable masses, raising concern for malignancy. Although systemic lead toxicity is rare, it should be considered in cases involving metallic fragments. Management depends on symptomatology and diagnostic uncertainty, with surgical removal indicated in symptomatic or suspicious cases.

Conclusion: This case highlights the importance of considering retained foreign bodies in the differential diagnosis of breast lumps, particularly in patients with a history of trauma. Early recognition and appropriate management can prevent unnecessary anxiety and ensure optimal patient outcomes.

Introduction

Foreign bodies within the breast are uncommon and infrequently encountered in routine clinical practice. Most reported cases involve iatrogenic materials, such as surgical clips or retained wire fragments following breast procedures. Non-iatrogenic foreign bodies - including metallic or plastic objects, lead fragments, and glass - are rarely described in the literature [1]. Airgun pellet injuries to the breast have been

Saif Al-Sahee^{1*}; Jonathan Adlem²; Layloma Hamidi Latifi¹

¹Surgical Breast Oncoplastic Unit, Maidstone Hospital, Kent, UK.

²Breast Radiology department, Maidstone Hospital, Kent, UK.

Received: Apr 26, 2026

Accepted: May 08, 2026

Published Online: May 15, 2026

Journal: Annals of Surgical Case Reports & Images

Online edition: <https://annsri.org>

Copyright: © **Al-Sahee S** (2026). This Article is distributed under the terms of Creative Commons Attribution 4.0 International License.

Cite this article: Al-Sahee S, Adlem J, Hamidi Latifi L. Retained air rifle pallet presenting as a breast lump eight years after injury. *Ann Surg Case Rep Images*. 2026; 3(1): 1128.

Keywords: Breast foreign body; Airgun pellet injury; Lead toxicity; Delayed presentation.

reported, particularly in younger male patients; however, these cases are likely underreported, which contributes to delayed diagnosis or suboptimal management [2].

Lead toxicity secondary to retained bullet injuries is a rare but likely under-recognised complication of penetrating gunshot injuries, with diagnosis often delayed for months or years due to non-specific clinical features. In symptomatic patients with elevated blood lead levels, management with chelation therapy

and surgical removal of retained fragments has been associated with clinical improvement [3].

The management of foreign bodies depend on several factors, including the presence of symptoms such as pain, infection, or palpable mass. The nature of the foreign body is also important, as certain materials might be toxic, contaminated, or associated with long-term tissue reaction. In some cases, foreign bodies may induce dense fibrotic response, potentially mimicking malignancy at clinical or radiological assessment [4].

A limited number of cases describing the removal of breast foreign bodies have been reported. Palpable lesions are typically amenable to surgical excision under local or general anaesthesia. In contrast, deep or non-palpable lesions often require image guided localisation, radioactive seed or TAG localisation, or intraoperative fluoroscopic guidance [1,5].

We report a case of a retained lead airgun pellet within the left breast, successfully removed under local anaesthesia in a patient presenting eight years after the initial injury. This case is notable for the delayed presentation and highlights diagnostic and management challenges, including potential lead toxicity.

Case presentation

A 25-year-old female presented to our breast one-stop clinic with a history of an air rifle pellet injury sustained eight years previously with concern for a retained foreign body in the left breast. The initial injury involved a penetrating wound to the lower inner quadrant.

At the age of 17, she was accidentally shot by a friend using an airgun from a distant approximately 1.5 meters. She attended the emergency department at the time, where clinical assessment and chest radiography were performed and was discharged without further intervention.

She re-presents after noticing a firm lump medial to the scar from the previous injury. She was initially evaluated privately by a plastic surgeon, who identified a retained foreign body and raised concerns regarding potential lead toxicity, prompting referral to our breast unit for further assessment.

On presentation, general examination was unremarkable. Local examination revealed scars consistent with previous mastopexy performed five years after the initial injury. A scar was noted in the lower inner quadrant of the left breast, with a palpable firm mass approximately 5 cm medial to this site (Figure 1).

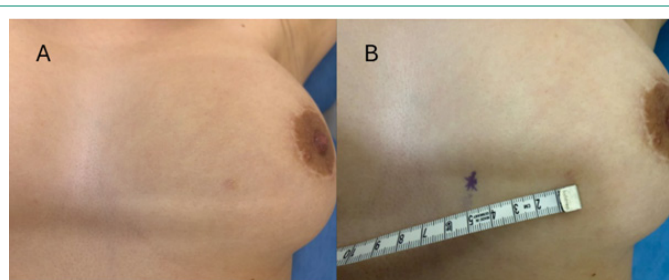


Figure 1: (A) Clinical photograph of the left breast demonstrating a subtle contour change with a small visible scar corresponding to the previous site of airgun pellet injury. (B) pre-operative localization showing the marked site of the palpable lesion (indicated by skin marker), with measurement demonstrating its position relative to surrounding anatomical landmarks.

Investigation included imaging and assessment of blood lead level. The Chest x-ray performed at time of injury was reviewed demonstrating the retained foreign body with no additional concerning features. Ultrasound examination confirmed a densely echogenic focus with posterior acoustic shadowing at the medial aspect of the left breast (Figure 2). Mammogram was not performed due to patient's young age. Blood lead level was assessed and found to be within normal range ($<0.10\mu\text{mol/L}$).

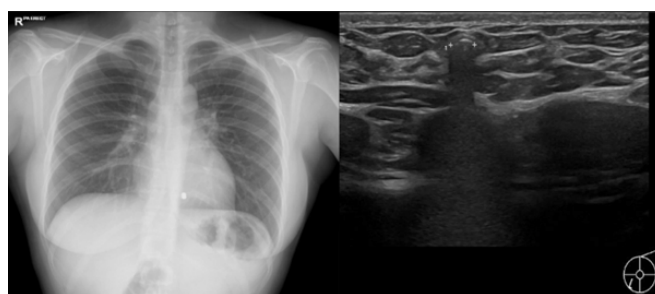


Figure 2: Chest radiograph (left) demonstrating a small, well-circumscribed radio-opaque density overlying the left breast, consistent with a retained airgun pellet. Ultrasound examination (right) shows a corresponding densely echogenic focus within the breast tissue with marked posterior acoustic shadowing, characteristic of metallic foreign body.

The patient was consented for surgical removal of the foreign body under local anaesthesia. The procedure was performed under aseptic technique. An incision was made along Langer's lines, followed by successful retrieval of the foreign body. Haemostasis was achieved, and wound was closed using absorbable sutures (Figure 3).

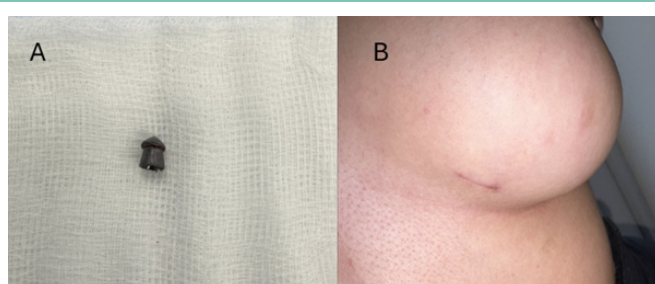


Figure 3: (A) Retrieved airgun pellet following surgical excision. (B) 2-weeks postoperative appearance of the left breast demonstrating a small, well-healed incision scar with satisfactory cosmetic outcome.

The patient tolerated the procedure well and was discharged on the same day without complications. At 2-week Follow up, wound had healed satisfactorily, and the patient was discharged with no requirement for further follow-up.

Discussion

Foreign bodies within the breast are uncommon, with airgun pellets reported only rarely and more frequently in younger female patients. The literature describes a range of retained materials, including iatrogenic objects such as surgical clips and drains, as well as incidental metallic fragments identified on screening or following trauma. More severe presentations, including gunshot injuries, have also been described and may result in significant tissue damage requiring surgical intervention. However, reports specifically describing retained airgun pellets within the breast are limited [2,6].

From a pathological perspective, inert foreign bodies typically elicit a local tissue response characterised by fibrous encapsulation, effectively isolating the material from surrounding

tissue [7]. Airgun pellets are predominantly composed of lead (approximately 95%), with smaller proportions of tin and antimony [8]. Although systemic toxicity is uncommon, cases of lead poisoning have been reported, particularly after swallowing and in association with ocular injuries [2]. In the present case, the patient exhibited no systemic manifestations, and blood lead levels were within normal limits.

Foreign body granuloma formation represents another important consideration, as it may mimic breast malignancy both clinically and radiologically [7]. Histologically, these lesions are characterised by multinucleated giant cells, including Langhans-type or foreign body-type giant cells, surrounding the retained material. Radiologically, this may present as suspicious calcifications or masses on mammography, posing a diagnostic challenge [9].

Management of retained breast foreign bodies depends on symptomatology, location, and risk of complications. Asymptomatic cases may be managed conservatively; however, symptomatic patients or those at risk of infection, lead toxicity, or diagnostic uncertainty typically require surgical removal. Palpable and superficial lesions can often be excised under local anaesthesia, whereas deeper or non-palpable lesions necessitate image-guided localisation techniques, such as wire-guided or radio-guided approaches [10]. In this case, the foreign body was superficial and palpable, allowing for straightforward excision without the need for localisation.

Conclusion

This case highlights the rare occurrence of a retained airgun pellet within the breast, presenting several years after the initial injury. Although foreign bodies may remain asymptomatic, they can pose diagnostic challenges by mimicking malignancy and may carry risks of local or systemic complications, including lead toxicity. Careful clinical and radiological assessment is essential to guide management. Surgical removal should be considered in symptomatic patients or when diagnostic uncertainty exists.

Clinicians should maintain a high index of suspicion for retained foreign bodies in the differential diagnosis of breast lesions, particularly in patients with a history of prior trauma.

References

1. Baysal H, Eren T, Erdem G, Karatas C, Baysal B, Alimoglu O. Foreign body in the breast: a case report. *Cureus*. 2024; 6: 73162.
2. Gupta M, Rizvi A, Vig H. Accidentally lodged airgun pellet in maxilla during childhood play retrieved surgically after a decade. *BMJ Case Rep*. 2021; 14: 246709.
3. Kershner EK, Chambers A, Wills BK, Cumpston KL. Retained bullets and lead toxicity: a systematic review. *J Med Toxicol*. 2022; 18: 1176-1186.
4. Wakabayashi M, Reid JD, Bhattacharjee M. Foreign body granuloma caused by prior gunshot wound mimicking malignant breast mass. *AJR Am J Roentgenol*. 1999; 173: 321-322.
5. Scaperrotta G, Capalbo E, Cartia F. Breast foreign body extraction using the breast lesion excision system. *J Vasc Interv Radiol*. 2015; 26: 1183.
6. Nwagbara VI, Asuquo ME, Agbor C, Nwachukwu IE. Gunshot (pellets) injury of the breast: a case report. *Int J Med*. 2013; 1: 20-22.
7. Anderson JM, Rodriguez A, Chang DT. Foreign body reaction to biomaterials. *Semin Immunol*. 2008; 20: 86-100.
8. Kershner EK, Tobarran N, Chambers A, Wills BK, Cumpston KL. Retained bullets and lead toxicity: a systematic review. *J Med Toxicol*. 2022; 18: 1176-1186.
9. Illman JE, Terra SB, Clapp AJ, Hunt KN, Fazzio RT, Shah SS, et al. Granulomatous diseases of the breast and axilla: radiological findings with pathological correlation. *Insights Imaging*. 2018; 9: 59-71.
10. Aydogan F, Atasoy D, Olgun DC, Dikici AS, Aliyev A, Gazioglu E. Extraction of a foreign body from the breast parenchyma using radioguided occult lesion localisation (ROLL) technique: a new approach. *Br J Radiol*. 2010; 83: 147-149.